

A Radiostereometric Analysis of Movements of the Sacroiliac Joints During the Standing Hip Flexion Test

Bengt Sturesson, MD,* Alf Uden, MD, PhD,† and Andry Vleeming, PhD‡

Study Design. The standing hip flexion test was evaluated by using a radiostereometric analysis.

Objectives. To evaluate whether the commonly used standing hip flexion test reflects movement in the sacroiliac joints, or whether the increased load of one sacroiliac joint also reduces the mobility of the other sacroiliac joint according to the theory of form and form closure in the sacroiliac joints.

Summary of Background Data. The standing hip flexion test, used frequently to analyze sacroiliac joint mobility, is advocated as a test for study of normal or impaired motion in the sacroiliac joint.

Methods. In this study, 22 patients considered to have sacroiliac pain were analyzed with radiostereometric analysis when standing and when performing the standing hip flexion test on the right and left sides.

Results. Very small movements were registered in the sacroiliac joints. When provoking one side, the rotations were small on both sides.

Conclusions. The small movements registered support the theory of form and force closure in the sacroiliac joints. The self-locking mechanism that goes into effect when the pelvis is loaded in a one-leg standing position probably obstructs the movements in the sacroiliac joints. Therefore, the standing hip flexion test cannot be recommended as a diagnostic tool for evaluating joint motion in the sacroiliac joints. [Key words: low back pain, pelvic pain, radiostereometric analysis, sacroiliac joint] *Spine* 2000;25:364-368

Sacroiliac joint (SIJ) mobility continues to be a major issue for debate.^{1,2,4,28} Postmortem analysis has shown that up to an advanced age, small movements are measurable under different load conditions.^{11,22,25} Reliable studies on living persons have been performed with radiostereometric analysis (RSA) of implanted markers,^{3,19-21} and with measurements based on implanted external Steinman rods.^{7,8}

Various clinical motion tests have been proposed for the study of normal and impaired motion of the SIJ^{5,6} but no thorough evaluation is available to clarify whether a motion test can specifically identify SIJ displacements.

The standing hip flexion test (SHFT) (also called the Giller's test or "rücklauf" test) has been used frequently to analyze SIJ mobility. The SHFT is performed with the

subject in a standing position. The posterior superior iliac spine is palpated with one thumb placed on it caudally and the other thumb placed at the S2 tubercle on the sacrum. The patient then maximally flexes the hip and knee on the tested side. If the movement is normal, it is assumed that the posterior superior iliac spine moves downward, but if the joint is "blocked," it moves upward in relation to the other side.^{6,12}

Potter and Rothstein¹² reported 47% agreement in an intertester reliability study of the SHFT test, and McCombe et al¹⁰ reported a kappa value of 0.4 in a reproducibility study of physical signs in low back pain. Landis and Koch⁹ stated that kappa values greater than 0.4 indicate a moderate strength of observer agreement. However, even a moderate level of agreement does not prove that the SHFT does in fact demonstrate movement in the SIJ.

The goal of the current study was to test the hypothesis that increased load significantly reduces the movements of the SIJ according to the theory of form and force closure proposed by Snijders et al.¹⁶ This theory implies that increased axial load and the effect of the muscles will force the surfaces of the SIJ closer together, thereby increasing the fitting. The forces of friction also will be increased by the counteracting transversely oriented muscles such as the oblique and transverse abdominal, gluteus maximus, coccygeus, and piriformis muscles,¹⁷ which also reduce the movement of the SIJ on the unloaded side.

The current study addressed the following questions: Which movements occur in the SIJ when patients alternately and maximally flex the left and right hips? Do both ilia move as a unit around the sacrum, or can provocation of one side cause the left and right SIJs to move in different directions? Is it possible to use the SHFT as a clinical diagnostic test?

■ Patients and Methods

The study population comprised 22 patients (18 women and 4 men), ages 19 to 45 years, who underwent physical evaluation for SIJ pain, including mobility tests and pain provocation tests. All patients were considered to have a SIJ syndrome, and the inclusion criteria included specific SIJ mobility and positive pain tests. The local ethics committee approved the study, and all patients gave written informed consent.

Each patient was examined independently by an orthopedic surgeon, a chiropractor, and two physiotherapists, and the diagnosis for each patient was reached by consensus of these clinicians. An SIJ syndrome was confirmed when either an asymmetric standing flexion test (in which the patient maximally bends forward from the standing position and the pos-

From the *Department of Orthopaedics, NVS Ängelholm, Sweden, the †Department of Orthopaedics, Malmö University Hospital, Lund University, Lund, Sweden, and the ‡Spine and Joint Centre Rotterdam and Research Group Musculoskeletal System, Department of Anatomy, Erasmus University Rotterdam, The Netherlands.

Acknowledgment date: November 4, 1998.

First revision date: February 15, 1999.

Acceptance date: April 22, 1999.

Device status category: 1.




Figure 1. Standing hip flexion position at the roentgen examination.

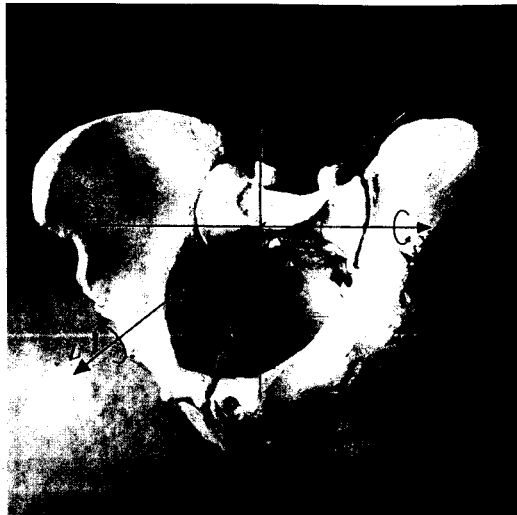


Figure 2. Pelvis with rotational axes.

terior superior iliac spine is palpated bilaterally and evaluated) or an SHFT was positive, or when two of the following pain tests were positive: the flexion-adduction test (in which the patient assumes the supine position with tested hip and knee in 90° of flexion and the hip is moved gently in adduction), the hyperextension test (in which the patient assumes the prone position, with one hand of the examiner stabilizing the sacrum and the other hand extending one leg), or the sacral springing test (in which patient assumes the prone position and pressure is applied to the apex of the sacrum).⁵ The intertester reliability with the SHFT was poor (kappa value nonsignificant in 11 of the 12 comparisons).¹⁸ Most of the patients were included on the basis of positive pain provocation tests. Of these 22 patients, 15 had unilateral symptoms.

Tantalum balls with a diameter of 0.8 mm and a mass of 0.004 g were inserted percutaneously with the patient under local anesthesia using fluoroscopy. At least four markers were inserted into each ilium and the sacrum as previously described in detail.¹⁹ Approximately 14 days later, the RSA examination was performed in a roentgen room specially equipped for RSA. The patients were examined standing, standing on the right foot with the left hip maximally flexed, and standing on the left foot with the right hip maximally flexed (Figure 1). The patients also were examined in the supine position, prone position with hyperextension of the left hip, and prone position with hyperextension of the right hip as described in a previous study.¹⁹

The sacrum was defined as the fixed segment. The movements were described as rotation around the three axes in a body-oriented coordinate system (Figure 2), as well as helical axis rotation (screw axis rotation), referring to the axis around which the rotation actually occurs. The helical axis rotation is defined as the sum of the three rotations around the x, y, and z axes.²⁰

The RSA calculations were performed as described by Selvik

et al¹³⁻¹⁵ using the computer programs Kinlab, Kinerr and X-RAY 90.

The error of measurements was assessed using a plastic pelvic model with a similar pattern of implanted tantalum markers as reported in detail by Stuesson et al.¹⁹ The precision was assessed as a 99% confidence limit for each degree of freedom, based on standard deviations from zero and the two-sided Student's *t* test distribution ($2P = 0.01$ and $v = 20$). The smallest significant movement of rotation was 0.3°, 0.4°, 0.1°, and 0.4° for the transverse (x), longitudinal (y), sagittal (z) and helical axes, respectively. The corresponding value for translation was 0.2 mm along the x, y, and helical axes and 0.1 mm along the z axis.²⁰

The means and standard deviations (SD) of some mobility tests (Table 1, columns A-L) of the patients were presented in a previous study.¹⁹ In the current study, the individual data of all patients are presented in Table 1 so possible comparisons with the SHFT can be made (Table 1). The Student's *t* test for paired observations was used to analyze the data.

■ Results

When the SHFT was performed, the movements of the SIJ around the three axes were very small in all the patients. The innominate rotated a mean of 0.2° posteriorly. However, in some patients they rotated anteriorly. The mean rotation of the helical axis was 0.6°. In all cases, the translations were very small (mean, 0.3 mm) (Tables 2 and 3). This is much less than the movements of the SIJ that occur when a subject stands up from the supine position. The mean movement between the supine and standing positions was -1.0° on the left side and -1.2° on the right side around the x axis, and 1.2° on the left side and 1.3° on the right side around the helical axis (Table 1). Compared with the SHFT on the provoked

Table 1. Original Data of Sacroiliac Joint Movement in All 22 Patients Between Different Positions (A-T)*

Nr.	Positions																				
	A.	B.	C.	D.	E.	F.	G.	H.	I.	J.	K.	L.	M.	N.	O.	P.	Q.	R.	S.	T.	
1.	-1.4	-1.2	1.8	1.2	●	●	●	●	●	●	●	●	-0.1	0.0	0.8	0.3	0.0	-0.2	1.8	1.2	
2.	0.0	-0.7	1.1	0.7	●	●	●	●	●	●	●	●	●	-0.2	●	0.6	0.4	-0.4	0.6	1.0	
3.	-1.8	-1.8	1.9	1.8	●	●	●	●	●	●	●	●	-0.2	-0.1	0.5	0.7	0.5	0.0	0.5	0.5	
4.	-1.5	-1.7	1.5	1.7	1.6	1.7	1.7	1.7	1.8	2.2	1.8	2.2	-0.4	-0.1	0.5	0.4	0.0	-0.1	0.7	0.4	
5.	-1.4	-1.1	1.5	1.2	●	●	●	●	●	●	●	●	0.4	●	1.2	●	-0.9	-0.2	0.9	1.2	
6.	-0.2	-0.5	0.3	0.5	●	●	●	●	●	●	●	●	-0.2	-0.5	0.3	0.7	-0.3	-0.3	0.3	0.6	
7.	-1.6	-1.8	1.6	1.8	2.1	2.0	2.1	2.0	2.1	2.6	2.1	2.7	-0.3	-0.5	0.5	0.6	●	-0.2	●	1.0	
8.	-1.4	-1.5	1.7	1.5	●	●	●	●	●	2.1	●	2.2	-0.2	●	0.3	●	-0.5	0.2	0.5	0.3	
9.	-1.2	-1.1	1.3	1.2	1.9	1.8	2.0	1.9	1.2	2.3	1.2	2.3	-0.2	0.1	0.2	0.6	0.0	0.2	0.2	0.5	
10.	-1.0	-1.0	1.0	1.0	2.3	1.6	2.3	2.0	1.4	1.9	1.6	2.4	-0.2	-0.1	0.4	0.3	0.2	-0.3	0.3	0.6	
11.	-1.6	-2.0	1.6	2.2	2.3	2.5	2.3	2.7	1.8	2.9	1.9	3.1	-0.5	0.1	1.4	0.2	-0.8	0.2	0.9	0.8	
12.	-0.3	-0.6	2.0	0.6	1.6	1.4	2.0	1.5	1.3	1.9	1.7	1.9	0.1	-0.3	0.8	0.3	0.7	-0.2	1.8	0.4	
13.	-1.6	-1.9	1.6	2.0	3.3	3.0	3.3	3.0	2.9	3.6	3.0	3.8	-0.1	0.1	0.2	0.4	-0.2	0.1	0.3	0.2	
14.	-1.1	-1.3	1.2	1.4	2.0	2.0	2.2	2.0	0.8	1.8	1.1	2.0	-0.4	-0.3	0.8	0.6	-1.0	-0.3	1.1	0.5	
15.	-1.8	-1.9	1.8	2.1	2.7	2.4	2.8	2.4	2.3	2.9	2.3	3.0	0.0	-0.2	0.5	0.4	0.0	0.0	0.8	0.7	
16.	-0.6	-0.7	0.6	0.7	2.2	1.9	2.3	2.0	1.4	1.9	1.4	1.9	0.0	-0.2	0.5	0.5	0.2	0.0	0.2	0.7	
17.	-0.6	-0.9	0.7	0.9	1.7	1.2	1.8	1.3	1.2	1.9	1.2	2.0	0.5	-0.4	1.0	0.4	-0.1	0.2	0.2	0.5	
18.	-0.7	-0.7	0.7	0.9	1.6	1.0	1.6	1.1	1.2	2.2	1.5	2.3	-1.0	-1.4	1.2	1.8	0.1	-0.2	0.1	1.1	
19.	-0.1	-0.7	0.2	0.7	●	●	●	●	●	●	●	●	●	-1.0	-1.0	1.2	1.1	-0.8	-0.6	0.8	0.8
20.	-1.0	-1.0	1.0	1.2	1.6	0.8	1.6	0.9	0.6	1.2	0.7	1.3	-0.5	0.2	0.5	0.5	0.6	-0.7	0.8	0.7	
21.	-1.0	-1.0	1.0	1.1	3.1	1.8	3.9	1.8	1.6	2.5	1.8	2.6	-0.1	-0.1	0.4	0.5	-0.2	-0.6	0.8	0.3	
22.	-0.9	-1.1	1.0	1.3	2.0	1.8	2.0	1.6	1.2	2.1	1.7	2.3	0.4	0.1	0.6	0.3	●	-0.1	●	0.8	
Mean	-1.0	-1.2	1.2	1.3	2.1	1.8	2.3	1.9	1.5	2.2	1.7	2.4	-0.2	-0.2	0.7	0.6	-0.1	-0.2	0.7	0.7	
SD	0.6	0.5	0.5	0.5	0.5	0.6	0.6	0.6	0.6	0.6	0.6	0.6	0.4	0.4	0.4	0.4	0.5	0.3	0.5	0.3	

* Rotation in degrees. Sacrum is the fixed segment.
 A = supine to standing x-axis left side; B = supine to standing x-axis right side; C = supine to standing helical axis left side; D = supine to standing helical axis right side; E = standing to prone with hyperextension of the left hip x-axis left side; F = standing to prone with hyperextension of the left hip x-axis right side; G = standing to prone with hyperextension of the left hip helical axis left side; H = standing to prone with hyperextension of the left hip helical axis right side; I = standing to prone with hyperextension of the right hip x-axis left side; J = standing to prone with hyperextension of the right hip x-axis right side; K = standing to prone with hyperextension of the right hip helical axis left side; L = standing to prone with hyperextension of the right hip helical axis right side; M = standing to standing with the left hip maximally flexed (SHFT) x-axis left side; N = standing to standing with the left hip maximally flexed (SHFT) x-axis right side; O = standing to standing with the left hip maximally flexed (SHFT) helical axis left side; P = standing to standing with the left hip maximally flexed (SHFT) helical axis right side; Q = standing to standing with the right hip maximally flexed (SHFT) x-axis left side; R = standing to standing with the right hip maximally flexed (SHFT) x-axis right side; S = standing to standing with the right hip maximally flexed (SHFT) helical axis left side; T = standing to standing with the right hip maximally flexed (SHFT) helical axis right side; ● = missing value.

side, the differences were highly significant: Table 1, columns A-M: $P < 0.001$; C-O: $P < 0.001$; B-R: $P < 0.001$; and D-T: $P < 0.001$, respectively.

When the SHFT was performed on one side, the magnitude of rotation was the same on both sides, and the mean difference was 0.06° (x axis and helical axis). This can be calculated from Table 1 (columns M-N, O-P, Q-R, and S-T). However, when the magnitude of the movements of the provoked and unprovoked sides in hyperextension with one hip in the prone position were

compared, the difference between the sides was significant: Table 1, columns E-F: $P < 0.01$; G-H: $P < 0.05$; I-J: $P < 0.001$; and K-L: $P < 0.001$, respectively.

When the SHFT (Table 1, columns M, O, R, and T) was compared with provocation of the SIJ by hyperextension of one hip in the prone position (Table 1, columns E, G, J, and L), the movement was 10-fold less around the x axis and three times less around the helical axis: Table 1, columns M-E: $P < 0.001$; O-G: $P < 0.001$; R-J: $P < 0.001$; T-L: $P < 0.001$, respectively.

Table 2. Data on Sacroiliac Joint Movement When Changing from Standing on Both Feet to Standing With the Left Hip Maximally Flexed

Rotation (degrees) Around the Axes	Joint	N	Mean	SD	Range
x-axis	left	21	-0.2	0.4	1.0-0.5
	right	20	-0.2	0.4	-1.4-0.2
y-axis	left	21	0.2	0.4	-0.7-0.8
	right	20	-0.1	0.4	-0.8-0.5
z-axis	left	21	0.2	0.3	-0.3-0.9
	right	20	0.1	0.3	-0.4-0.8
Helical axis	left	21	0.6	0.4	0.2-1.4
	right	20	0.6	0.4	0.2-1.8
Translation (mm) along the helical axis	left	21	0.3	0.2	0.1-1.1
	right	20	0.3	0.4	0.0-1.1

N = number of joints.

Table 3. Data on Sacroiliac Joint Movement When Changing From Standing on Both Feet to Standing With the Right Hip Maximally Flexed

Rotation (degrees) Around the Axes	Joint	N	Mean	SD	Range
x-axis	left	20	-0.1	0.5	-1.0-0.7
	right	22	-0.2	0.3	-0.7-0.2
y-axis	left	20	0.0	0.5	-1.1-1.8
	right	22	-0.2	0.5	-1.0-0.9
z-axis	left	20	0.1	0.4	-0.3-1.2
	right	22	-0.2	0.3	-0.8-0.5
Helical axis	left	20	0.7	0.5	0.1-1.8
	right	22	0.7	0.3	0.2-1.2
Translation (mm) along the helical axis	left	20	0.3	0.2	0.0-0.7
	right	22	0.3	0.2	0.0-0.8

N = number of joints.

Discussion

Clinical movement analysis of the SIJs remains a subject of discussion. The SHFT has been advocated as an important diagnostic tool in evaluating the sacroiliac syndrome.^{5,6} However, reliability studies so far lack sufficient diagnostic power.^{10,12}

The current study used the RSA, a very accurate and well-documented method, for three-dimensional analysis of small movements. The technique, developed by Selvik et al,^{13,15} was based on analytic photogrammetry and mathematical principles of rigid-body motion. A 1990 review article stated that more than 20,000 tantalum balls were implanted into approximately 2000 patients, with applications in almost every bone in the body, but that the technique was used mainly in the study of hip and knee prostheses¹⁴; RSA of the pelvis has been used in other studies.^{3,19-21,27} No adverse reactions have been reported, except for local pain over a few days when a percutaneous technique was used.

Because of the hazard associated with radiation, the ethics committee did not allow double examinations for reliability purposes in the patients. Therefore, a technique involving repeated examinations of a plastic pelvic model assessing the error of measurements was used. The standard deviations for rotation and translation between double examinations were calculated in another RSA study, with tantalum markers placed in the same region of the pelvis as in the current study.²¹ The result from that study showed an error of measurement comparable with the result from the plastic pelvic model.

The maximal movement that could be demonstrated in a previous study¹⁹ was a mean of 2.5°. This movement occurred when the subject changed from a prone unloaded position to a sitting loaded position. In that study, the movements were equal on both sides in all tested positions, except between the standing and prone positions with hyperextension of the ipsilateral hip. In these unloaded positions, it was possible to demonstrate a difference of 0.5° between provoked and unprovoked sides.

In contrast, in the current study, very small movements were found when rotation was provoked, with the

femur on one side used as a lever while the subject was standing on the other leg with full load on the SIJ of that side. Interestingly, in this situation, the movements of the SIJ were equal and small, even on the unloaded provoked side, indicating that during this test, the two ilia behave as one unit.

The mean values for the helical axis rotation (Tables 2 and 3) were higher than the mean values for the rotation around the orthogonal axes. The reason for this can be seen in the fact that rotation around the helical axis can show a only positive value, whereas the mean value of rotation around the orthogonal axes can be low if the direction of rotation differs between the patients.

A theoretical concept of the pelvic function was developed on the basis of anatomic and biomechanical studies.^{16,17,24,26} This concept introduces the principles of form and force closure related to the pelvis. Form closure refers to a stable situation with closely fitting joint surfaces, in which no additional forces are needed to maintain the state of the system, given the actual load situation. If the sacrum would fit in the pelvis with perfect form closure, no lateral forces would be needed. However, such a construction would make mobility in the SIJ practically impossible.

With force closure, both a lateral force and friction are needed to withstand the impact of the vertical load on the pelvis. Effective force transfer to withstand the shear forces is prevented by a combination of specific anatomic SIJ features (form closure), such as the wedge- and propeller-like form of the joint surfaces and the high friction coefficient.^{22,26} Muscles and ligaments also prevent shear forces by means of compression that can be adjusted to the specific loading situation (force closure).²³

The aforementioned theory predicts that when the pelvis is loaded (e.g., when the subject is in a standing position), the pelvis generally becomes self-locked with a small rotation of the sacrum nodding anteriorly relative to the ilia (nutation). This model is confirmed by mobility studies on living subjects.^{3,8,19} When the subject, already in a standing position, lifts one leg, the load transferred through the ipsilateral SIJ is then at least doubled.^{16,17} If this theory is correct, then when a SHFT

is performed, a full range of movement in the SIJ should not occur.

The results of the current study support this theory, because only very small movements occurred in the SIJs when the SHFT was performed. These small movements could further increase the ligament tension in the pelvis and compress the SIJ. These findings also imply that the question as to whether the SHFT procedure has a sufficient level of inter- and intratester reliability is not of primary concern. The results clearly show that movements in the SIJ during the SHFT are so minute that external detection by manual methods is virtually impossible. Also, if movements do occur, they are similar on both sides, so it is impossible to manually detect differences between right and left SIJ by means of the SHFT.

From this perspective, the reason why the SHFT is reported to have such a low inter- and intratester reliability seems obvious.^{10,12} The patients in the current study also were included in a study assessing the reliability of different SIJ tests.¹⁸ In that study, 37 patients were assessed by the same research group who examined the current study population: an orthopedic surgeon, two experienced physiotherapists, and a chiropractor specially trained in pelvic examination. The examinations of the patients performing the SHFT on each side were compared among all the examiners. In only 1 comparison out of 12 was a significant kappa value found, indicating that the SHFT had no intertester reliability.

In comparing movements of the posterior iliac spines relative to each other when the SHFT procedure is executed, external movement of the pelvis on the hip joints may give the impression of internal pelvic motion in the SIJs. What is assumed to be detectable as dissimilar movement of the SIJ during the SHFT is probably an illusion.

Although the current study was limited to patients with symptoms in the SIJ region, the findings probably are applicable to others because the degree of mobility was the same in both the symptomatic and asymptomatic joints, and the magnitude of the movements within the groups shows an almost normal distribution (Table 1, columns A-D).¹⁹ Therefore, the SHFT cannot be recommended as a diagnostic tool for evaluating joint motion in the SIJs.

References

1. Albee FH. A study of the anatomy and the clinical importance of the sacroiliac joint. *JAMA* 1909;53:1273-6.
2. Colachis SC Jr, Worden RE, Brechrol CO, Strohm BR. Movement of the sacroiliac joint in the adult male: A preliminary report. *Arch Phys Med Rehabil* 1963;44:490-8.
3. Egund N, Olsson TH, Schmid H, Selvik G. Movements in the sacroiliac joints demonstrated with roentgen stereophotogrammetry. *Acta Radiol Diagn* 1978;19:833-46.
4. Goldthwait J, Osgood RB. A consideration of the pelvic articulations from an anatomical, pathological, and clinical standpoint. *Boston Med Surg J* 1905;152:593-601.

5. Grieve GP. The sacroiliac joint. *Physiotherapy* 1976;62:384-400.
6. Kirkaldy-Willis WH, Hill RJ. A more precise diagnosis for low back pain. *Spine* 1979;4:102-9.
7. Kissling RO, Brunner Ch, Jacob HAC. Zur Beweglichkeit der Iliosacralgelenke in vitro. *Z Orthop* 1990;128:282-8.
8. Kissling RO, Jacob HAC. The mobility of the sacroiliac joint in healthy subjects. In: *The Integrated Function of the Lumbar Spine and Sacroiliac Joints*. San Diego, CA: Second Interdisciplinary World Congress on Low Back Pain, 1995:411-422.
9. Landis RJ, Koch GG. The measurement of observer agreement for categorical data. *Biometrics* 1977;33:159-74.
10. McCombe PF, Fairbank JCT, Cockersole BC, Pynsent PB. Reproducibility of physical signs in low back pain. *Spine* 1989;14:908-18.
11. Miller JAA, Schultz AB, Andersson GBJ. Load-displacement behaviour of sacroiliac joints. *J Orthop Res* 1987;5:92-101.
12. Potter NA, Rothstein JM. Interobserver reliability for selected clinical tests of the sacroiliac joint. *Phys Ther* 1985;11:1671-5.
13. Selvik G. A Roentgen Stereophotogrammetric Method for the Study of the Kinematics of the Skeletal System. Lund, Sweden, AV-Centralen, Thesis 1974. Reprinted in *Acta Orthop Scand* 1989;60(Suppl):232.
14. Selvik G. Roentgen stereophotogrammetric analysis. *Acta Radiologica* 1990;31:113-26.
15. Selvik G, Alberius P, Aronson S. A roentgen stereophotogrammetric system. *Acta Radiol Diagn* 1983;29:343-52.
16. Snijders CJ, Vleeming A, Stoeckart R. Transfer of lumbosacral load to iliac bones and legs: Part 1. Biomechanics of self-bracing of the sacroiliac joints and its significance for treatment and exercise. *Clin Biomech* 1993;8:285-94.
17. Snijders CJ, Vleeming A, Stoeckart R. Transfer of lumbosacral load to iliac bones and legs: Part 2. Loading of the sacroiliac joints when lifting in a stooped posture. *Clin Biomech* 1993;8:295-301.
18. Sturesson B, Ekeblom A, Rylander G, Nelson NE. Reliability of sacroiliac joint tests, an inter- and intraexaminer trial. In: *Load and Movement of the Sacroiliac Joint (Thesis)*. Lund, Sweden: Lund University, 1999.
19. Sturesson B, Selvik G, Udén A. Movements of the sacroiliac joints: A roentgen stereophotogrammetric analysis. *Spine* 1989;14:162-5.
20. Sturesson B, Udén A, Onsten I. Can an external frame fixation reduce the movements of the sacroiliac joint? A radiostereometric analysis. *Acta Orthop Scand* 1999;70:42-6.
21. Tullberg T, Blomberg S, Branth B, Johnsson R. Manipulation does not alter the position of the sacroiliac joint. *Spine* 1998;23:1124-9.
22. Vleeming A. The sacroiliac joint [Thesis]. Rotterdam: Erasmus University, 1990.
23. Vleeming A, Snijders CJ, Stoeckart R, Mens JMA. A new light on low back pain. In: *The Integrated Function of the Lumbar Spine and Sacroiliac Joints*. San Diego, CA: Second Interdisciplinary World Congress on Low Back Pain, 1995:149-68.
24. Vleeming A, Stoeckart R, Volkers ACW, Snijders CJ. Relation between form and function in the sacroiliac joint: Part 1. *Spine* 1990;15:130-2.
25. Vleeming A, Van Wingerden JP, Dijkstra PF, Stoeckart R, Snijders CJ, Stijnen T. Mobility in the sacroiliac joints in the elderly: A kinematic and radiological study. *Clin Biomech* 1992;7:170-6.
26. Vleeming A, Volkers ACW, Snijders CJ, Stoeckart R. Relation between form and function in the sacroiliac joint: II. Biomechanical aspects. *Spine* 1990;15:133-5.
27. Walheim G, Selvik G. Mobility of the pubic symphysis: *In vivo* measurements with an electromechanical and a roentgen stereophotogrammetric method. *Clin Orthop* 1984;191:129-35.
28. Weisl H. The movements of the sacroiliac joint. *Acta Anat* 1955;23:80-91.
29. White III AA, Panjabi MM. *Textbook: Clinical Biomechanics of the Spine*. Philadelphia: JB Lippincott, 1991:90.

Address reprint requests to

Bengt Sturesson, MD
 Department of Orthopaedics
 Ängelholm Hospital
 S-262 81 Ängelholm
 E-mail: bengt.sturesson@angelholm.mail.telia.com